Neuroimaging Markers of Cerebral Amyloid Angiopathy in the Absence of Symptomatic Lobar Intracerebral Hemorrhage.

Sergi Martinez-Ramirez, MD
StrokeNet Fellow
Hemorrhagic Stroke Research Program
Massachusetts General Hospital

Mentors: Anand Viswanathan, MD, PhD; Steven M.Greenberg, MD,PhD

Disclosures

- None

Cerebral amyloid angiopathy

- Deposition of β-amyloid peptide over media and adventitia of cortical and leptomeningeal arteries.
- Sporadic and hereditary forms
- Prevalence increases with age (85% of population over 80 have some degree, 20% have moderate/severe) –*Arvanitakis et al. Ann Neurol 2011*
- Strong association with Alzheimer's disease (CAA more frequent and severe)
- **Classic presentation: symptomatic lobar ICH (most common cause in the elderly)** Other: cognitive impairment, TFNE, silent forms

How we currently diagnose CAA

- Invasive: Brain pathological exam – only way to confirm Dx
- Non-invasive: - Boston Criteria
  - Pathologically validated
  - 1 lobar hemorrhage ("possible CAA") vs ≥2 strictly lobar hemorrhages ("probable CAA")
  - Highly specific (probable >possible)
  - Applies strictly to individuals with at least 1 lobar ICH

Greenberg et al. Stroke 1996
Knudsen et al. Neurology 2001

CAA is more than just ICH…

- In the elderly, CAA prevalence is way superior to prevalence of lobar ICH – non-hemorrhagic forms
- The finding of incidental lobar MB is more frequent than lobar ICH
- CAA, through vascular dysfunction, can also cause ischemia.
- Initial stages of CAA pathophysiology may involve issues in drainage of interstitial fluid (ISF) along perivascular spaces, potentially detectable on MR imaging

Alternative approaches to a non-invasive diagnosis of CAA

- APOE genotype?
- PET-amyloid imaging?
- fMRI?…

Promising but not currently applicable in clinical practice. Not sensitive and specific enough.

- MRI markers that have been there for a long time…and quite overlooked.
  - **Lobar MB (in the absence of lobar ICH)**
  - **A-P distribution of WMH**
  - **Dilated perivascular spaces in the white matter (WM-DPVS)**

Research interests (I)

- **Lobar MB in the absence of lobar ICH** Radiological-pathological study on MGH and Framingham cohorts
  (Martinez-Ramirez et al. 2014. Under review in Alzheimer's & Dementia)

- **A-P distribution of WMH**
  Center of WMH mass is more posteriorly located in CAA individuals compared to non-CAA individuals, even in the absence of lobar MB.
  (Thanprasertsuk/Martinez-Ramirez et al. Neurology 2014;83:1–7)

Figure 1 The reference point

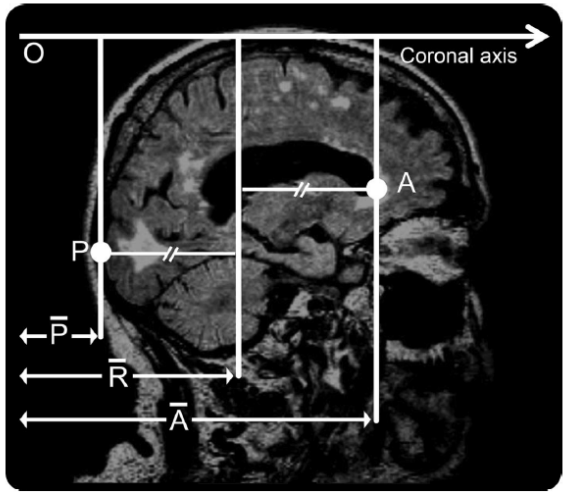

- **WM-DPVS**

Rationale behind the association between WM-DPVS and CAA

- BG-DVPS are more strongly associated with classic long-standing hypertension markers than WM-DPVS, in patients with ischemic stroke *(Doubal et al.2010, Rouhl et al. 2008)* and general population *(Yakushiji et al. 2014).*

- There is a relative increase of water content in the WM of AD patients. *(van Swieten et al.1991)*

- One pathologic study focused on the association between the retention of ISF within DPVS and the presence/severity of CAA *(Roher et al. 2003).*

In CAA, blockage of ISF drainage by vascular amyloid could favor the retrograde dilation of PVS into the white matter.

Research interests (II)

- **WM-DPVS**

In memory clinic patients, high burden of BG-DPVS is independently associated with hypertension. High burden of WM-DPVS is independently associated with lobar MB count. (Martinez-Ramirez et al. Neurology 2013;80:1–6)

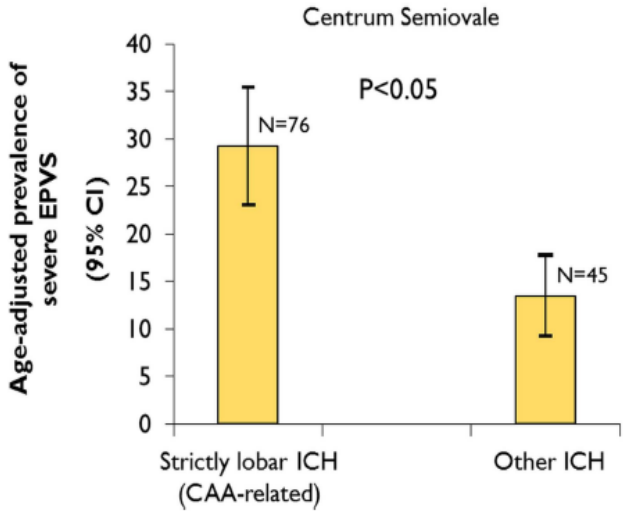

Charidimou et al. JNNP 2013

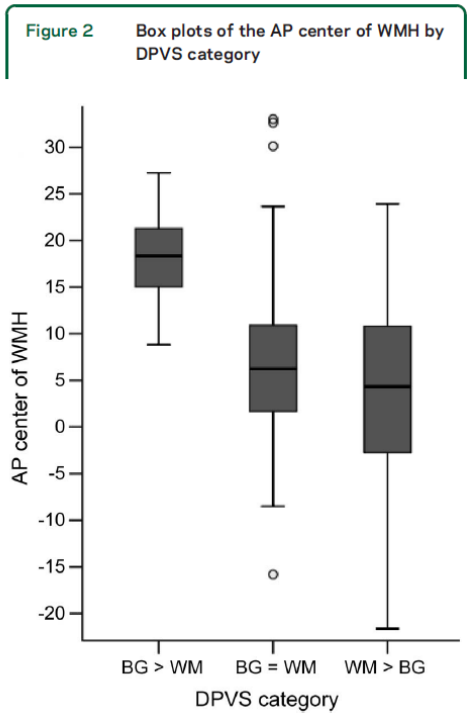

Thanprasertsuk/Martinez-Ramirez et al. Neurology 2014

WM-DPVS postulated as potential new CAA markers on a recent review on Lancet Neurology

Study aims

- To confirm the associations between WM-DPVS and CAA in cases with definite diagnosis of the disease.
- To explore differences in WM-DPVS burden between different CAA subgroups:
  - CAA with no hemorrhage
  - CAA with only MB
  - CAA with lobar ICH (+/- MB)
- To introduce a new quantitative method for DPVS assessment that might offer advantages compared to visual rating.

Study description

- In collaboration with Leiden University Medical Center.
- To confirm and refine the association of WM-DPVS with CAA (considering CAA phenotypic spectrum).
  - Using definitive diagnosis of CAA instead of surrogate markers.
  - Parallel study in both sporadic and hereditary CAA cohorts
    - Sporadic: pathological diagnosis, common form but plenty of interference by vascular risk factors and associated brain damage. **MGH cohort**
    - Hereditary: genetic diagnosis, rare form but less confounding by vascular risk factors. **Leiden cohort (CAA Dutch mutation)**
  - MGH cohort: subanalysis comparing WM-DPVS burden between macrobleeders (lobar ICH) vs microbleeders (only lobar MB) vs. non-bleeders
  - Leiden cohort: subanalysis comparing WM-DPVS burden between symptomatic carriers vs. asymptomatic carriers vs. non-carriers (controls)
  - Utilizing semi-quantitative DPVS measurements instead of visual rating

Study cohorts

- MGH cohort (sporadic CAA)
  - Modified from the original cohort for the MB-only Boston Criteria validation study.
  - 63 subjects
- Leiden cohort (hereditary CAA)
  - Symptomatic and Asymptomatic mutation carriers:
    - CHA (Cerebral Hereditary Angiopathy) outpatient clinic (LUMC)
    - Patient assocation
    - *All* DNA proven
  - 2 Control groups (comparable age)
  - 57 subjects

DPVS quantitative measurement

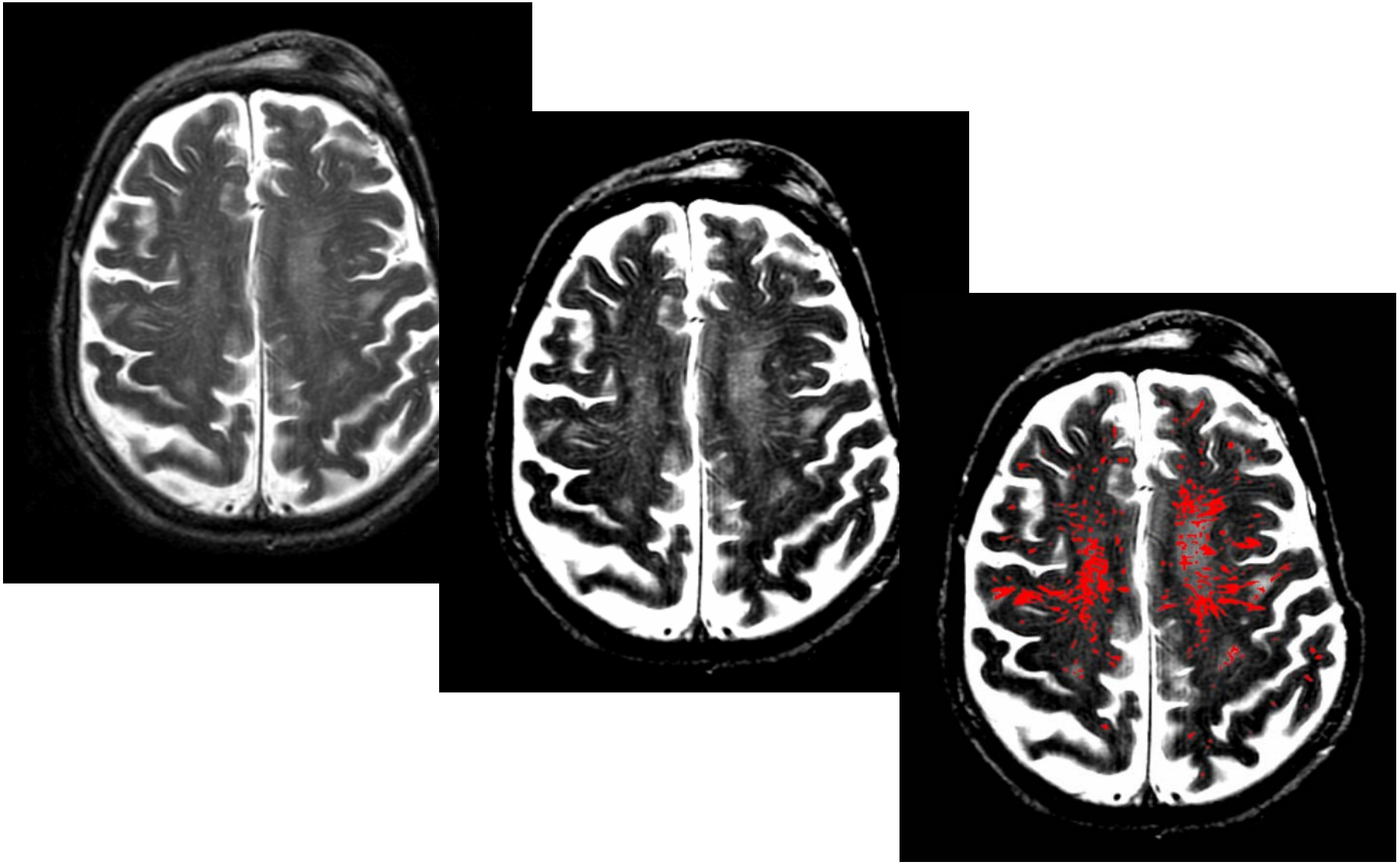

DPVS quantitative measurement

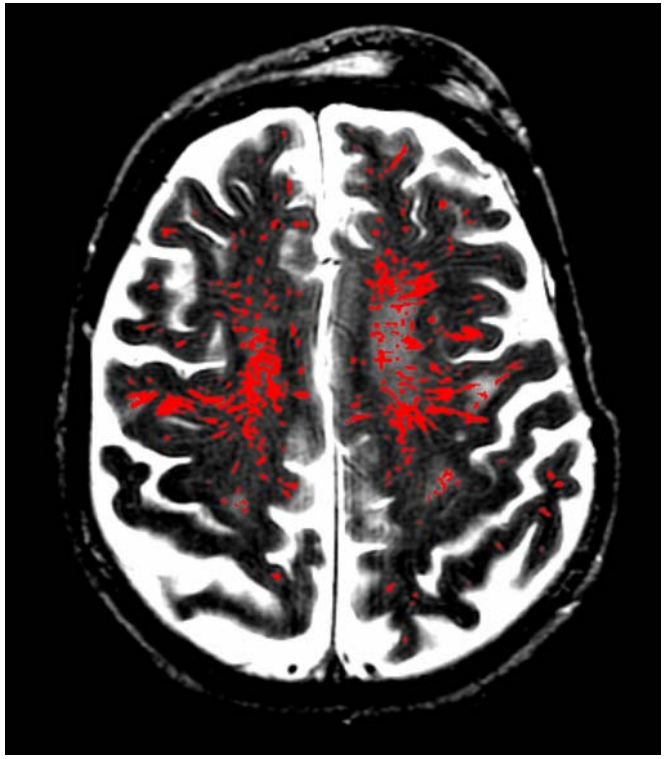

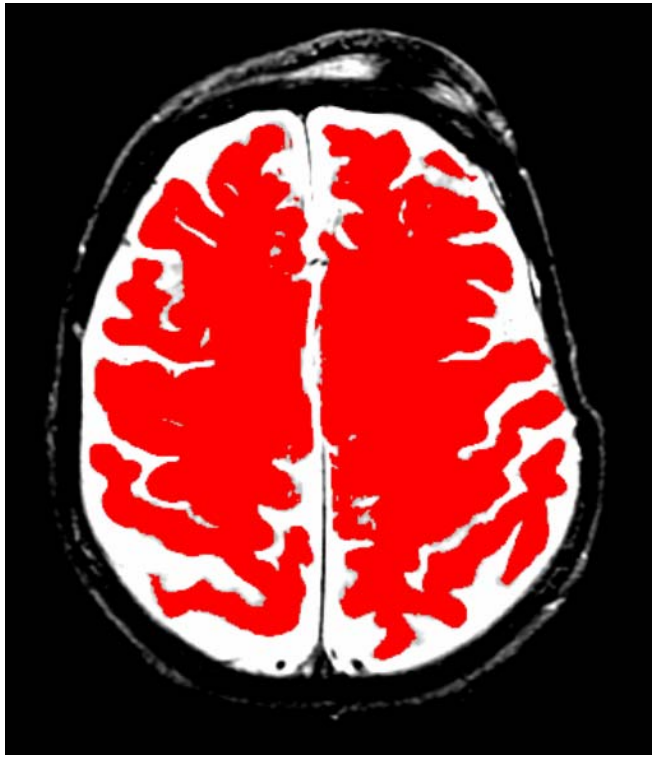

Relative CSO-DPVS area in a given brain slice:
CSO-DPVS area(cm2) / total brain area (cm2) x100

3.84 cm2 / 52.5 cm2 x 100 = 7.31%

DPVS quantitative measurement

- Intraclass correlation coefficient MGH-Leiden over 14 cases: 0.93 (excellent)

MGH cohort characteristics

(n=63)	
Age by MRI, years (mean ± SD)	73.5 ± 8.5
Female sex, n (%)	29 (46)
Hypertension, n (%)	41 (65)
WM-DPVS degree ≥ 3, n (%)	54 (85)
BG-DPVS degree ≥ 3, n (%)	43 (70)
CSO-DPVS area % (median, range)	4.2, 0.7-15.2
Autopsy study, n (%)	32 (51)
CAA, n (%)	46 (73)
CAA without any hemorrhage, n (%)	8 (17.4)
CAA with only MB, n (%)	17 (36.9)
CAA with ICH (+/- MB), n (%)	21 (45.7)

Sporadic CAA. Visual vs quantitative DPVS assessment

Distribution of CSO-DPVS areas across the cohort

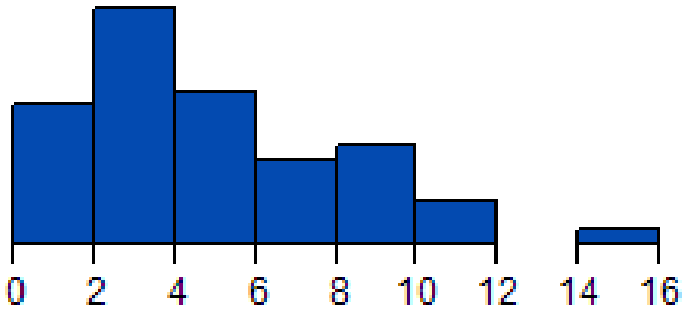

CSO-DPVS area by visual DPVS categories:
Poor discrimination of DPVS burden in the higher range. Clear ceiling effect.

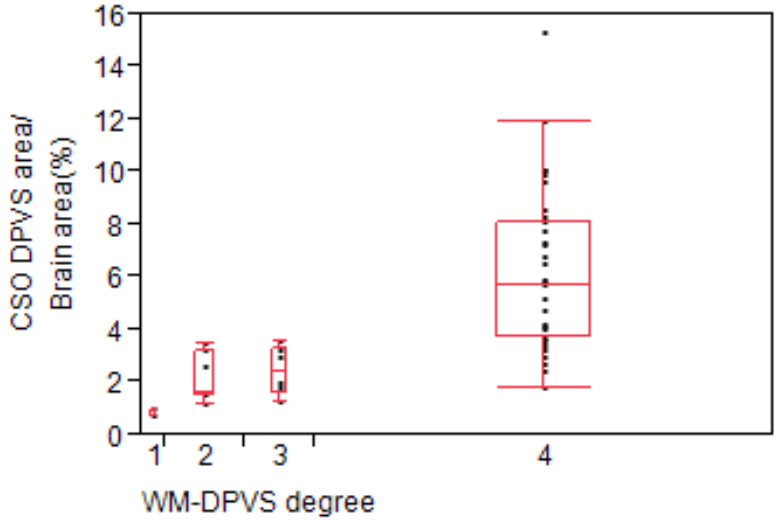

Sporadic CAA. CSO-DPVS and CAA - results

Comparison of CSO-DPVS area between CAA+ and CAA- subjects

(n=63)

Median test P<0.0001

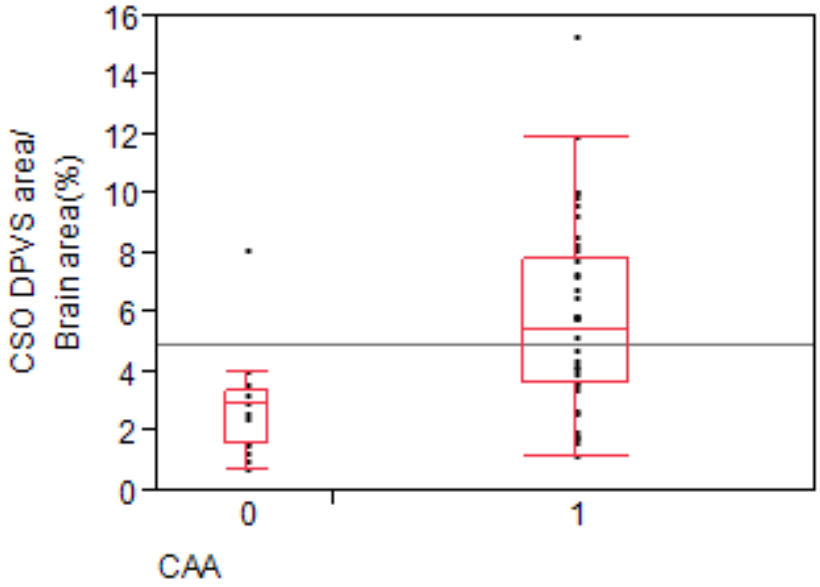

(Level of significance almost unchanged after adjusting for age, gender, hypertension and BG-DPVS degree)

Sporadic CAA.
CSO-DPVS area by CAA status/hemorrhage profile

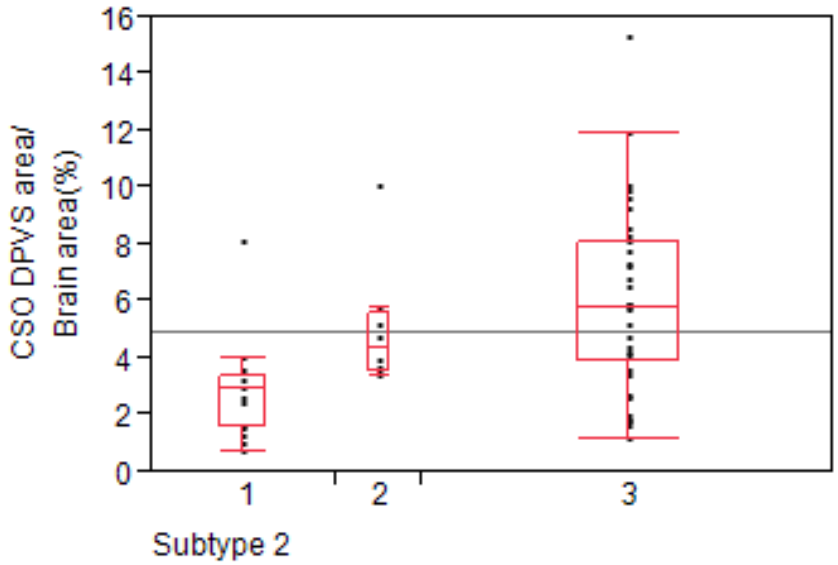

1=No CAA
2=CAA with no hemorrhage
3=CAA with any hemorrhage

Mann-Whitney test
p = 0.0001

Results remain unchanged after adjusting for age, gender, hypertension and BG-DPVS

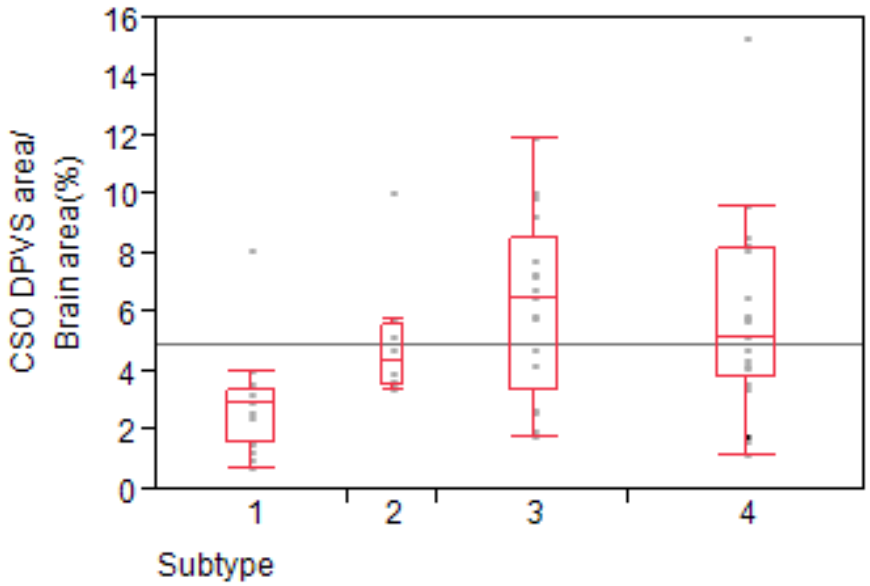

1=No CAA
2=CAA with no hemorrhage
3=CAA with only MB
4=CAA with ICH (+/-MB)

Mann-Whitney test
p = 0.0004

Results remain unchanged after adjusting for age, gender, hypertension and BG-DPVS

Leiden cohort characteristics

(n=57)	Symptomatic patients	Older controls	Asymptomatic patients	Younger controls
Number	15	17	12	13
Age, years (range)	54.9 (45-63)	57.2 (45-72)	34.3 (20-51)	35.7 (30-44)
Female sex, n(%)	9(60)	8(47)	9(75)	10(77)

Hereditary CAA. CSO-DPVS analysis by carrier status and presence of symptoms

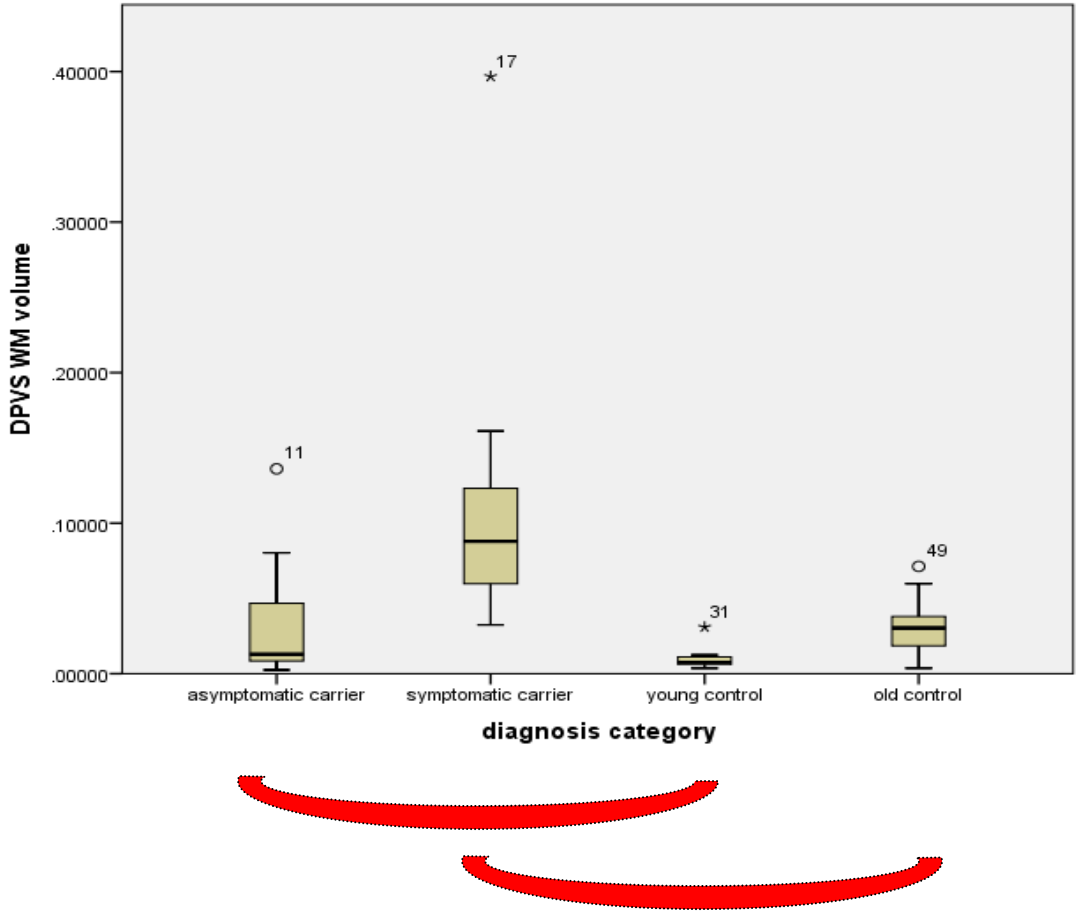

Symptomatic – old controls:
Mann Whitney without any corrections: $p < 0.0001$
Linear regression corrected for age, gender, BG-DPVS: $p = 0.003$

Asymptomatic – young controls:
Mann Whitney without any corrections: $p = 0.131$
Linear regression corrected for age, gender, BG-DPVS: $p = 0.135$

If the 2 control groups are collapsed into a single one, highly significant differences remain for symptomatic carriers but the trend observed for asymptomatic carriers gets lost.

Hereditary CAA-examples

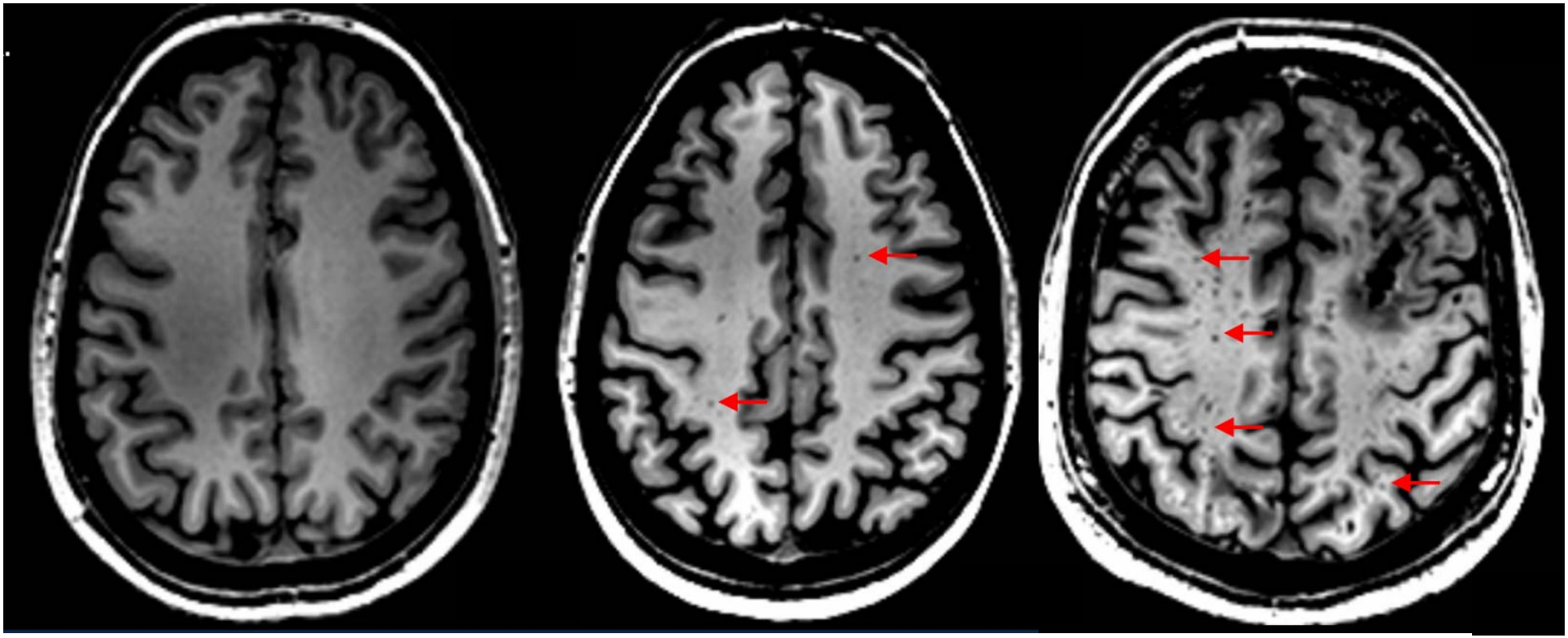

Control | Asymptomatic carrier | Symptomatic carrier

Images courtesy of S.van Rooden and M.van Buchem

Conclusions

- We confirmed that CAA is associated with significantly higher burden of WM-DPVS, both in sporadic and hereditary cases.

- High WM-DPVS burden seems to be associated with CAA even in the absence of symptomatic lobar hemorrhages, in the sporadic form (and maybe in the hereditary form).
  - Potential relevance in diagnosis of non-hemorrhagic forms? (similar to A-P WMH)
  - Potential relevance in overall early diagnosis of CAA? – sporadic>hereditary

- Quantitative measurement of WM-DPVS might offer better accuracy than current visual scales in detecting significant differences in burden between CAA and non-CAA subjects .
  - Need for method that relies less on raters' expertise and decreases workload
  - Whole brain analysis vs. regional analysis

Future steps

- To study if a spatial correlation between PVS dilation and CAA severity exists. → Work in progress (collaboration with Utrecht Medical Center)
- To understand the directionality of the WM-DPVS-CAA association.
  - Is PVS dilation a predisposing factor for amyloid stagnation? or
  - Is vascular amyloid deposition directly responsible for PVS dilation?
- To determine whether ↑WM-DPVS may be risk factor or early marker of CAA.

→ Detection and quantification of WM-DPVS and other markers of CAA and small-vessel disease on serial MRI studies in healthy population.
  - Rotterdam, Framingham

- To develop a more reliable and fast quantitative method to assess WM-DPVS in the whole brain. → Assistance from bioinformatics, bioengineers
- To identify methods that can be applied to clinical practice (i.e. presence of WM-DPVS in the temporal or occipital lobe yes/no) → Focused analysis of WM-DPVS on specific topographies in CAA and non-CAA subjects

Thank you